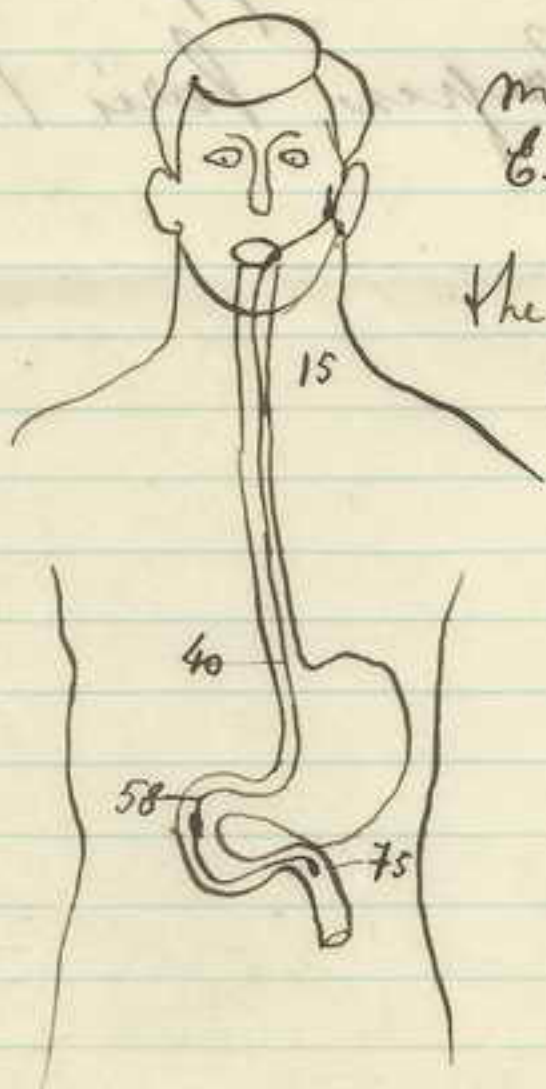


Worms primitivas

U. secundarias { anemia
tuberculosis
melena neonatorum
Quemaduras
etc.



método de
Citriform

The thread
impregnation
test.

Manuel Ferrer Torres



UNIVERSIDAD
DEL SALVADOR

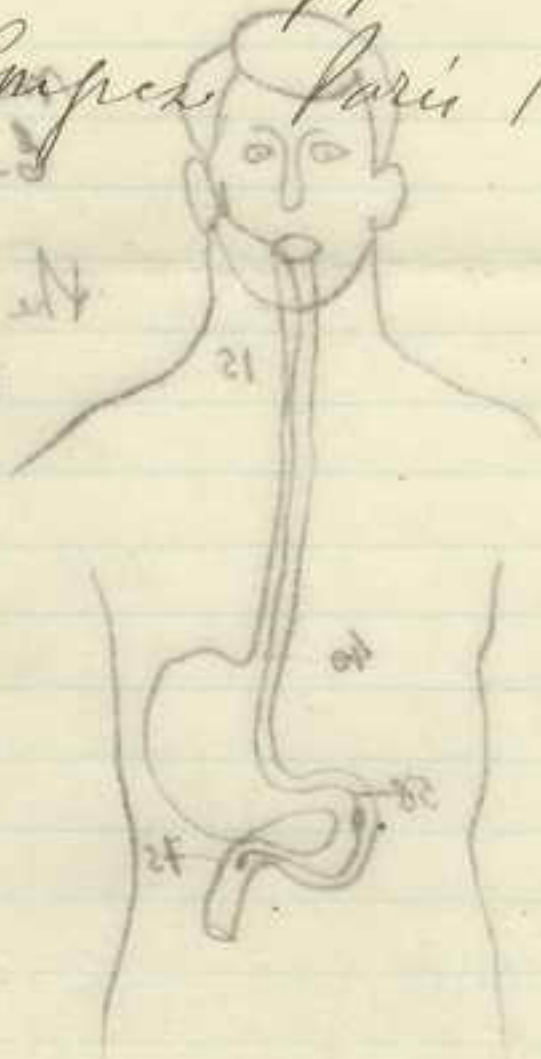
11

Werner
Fischer
Mehner
Pumacher
etc.

Ricard. Rapport

à l'Institut
Carpes Paris 1910

de l'Institut
de l'Institut
de l'Institut



Belladonna

extracto

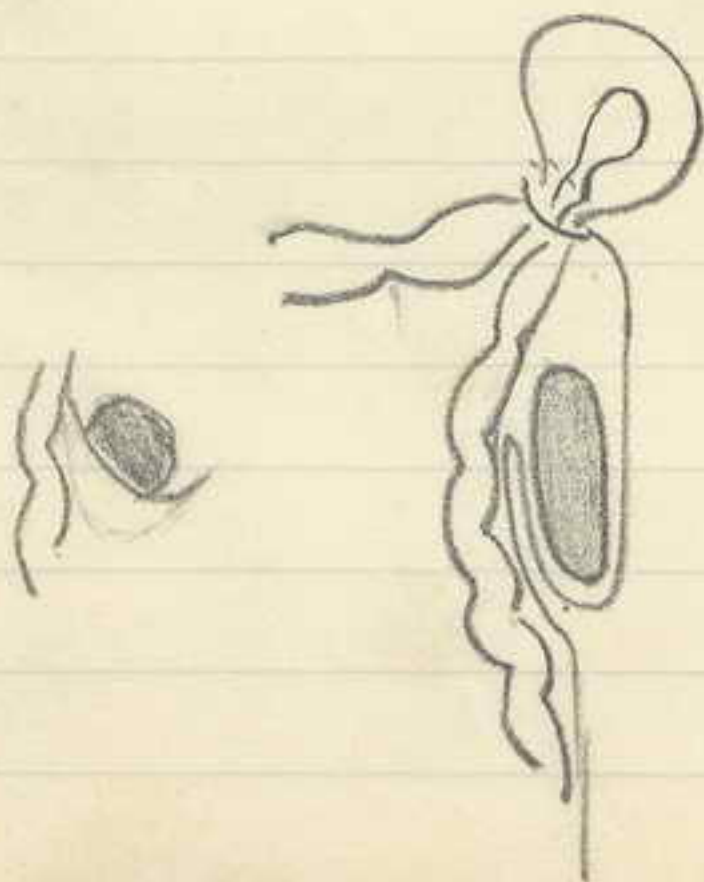

0.01

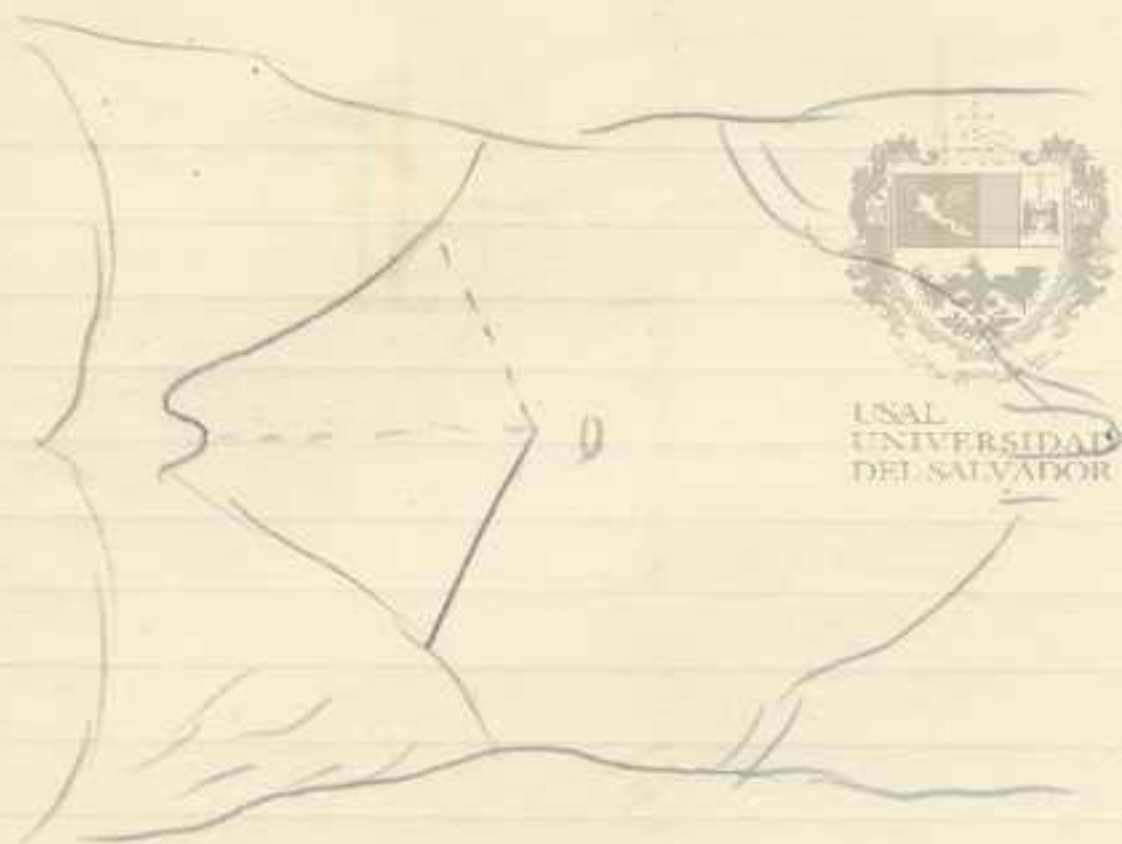
atropina

0.001

Pintura belladonna $\frac{1}{10}$

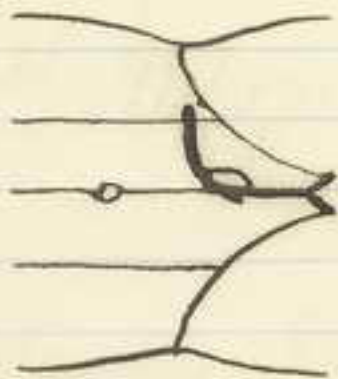

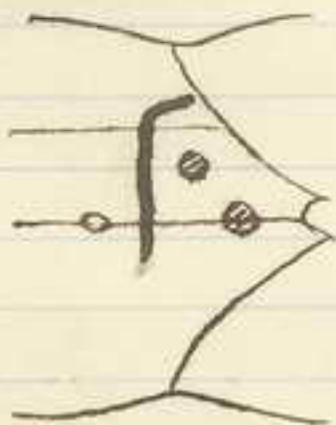
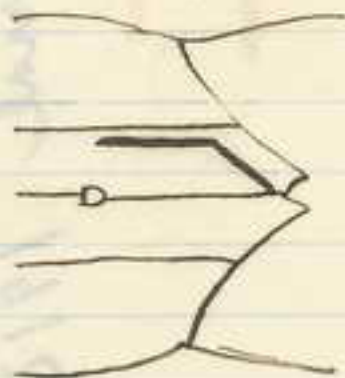

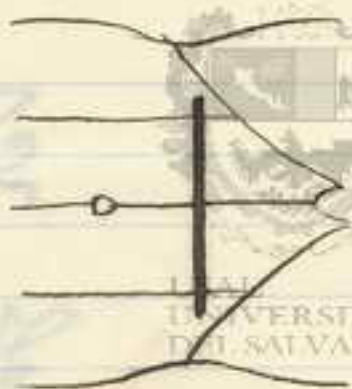
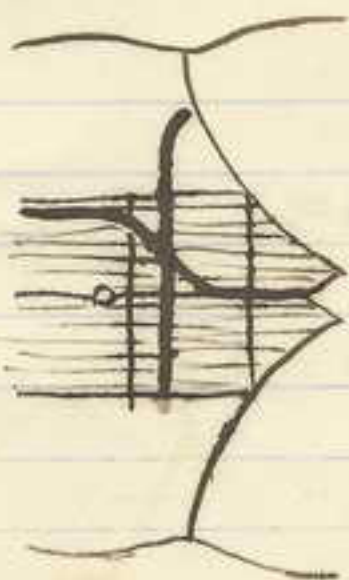
4 gramos





Iniección de Kausch
para biliares

J. Chir. 1911 p. 334




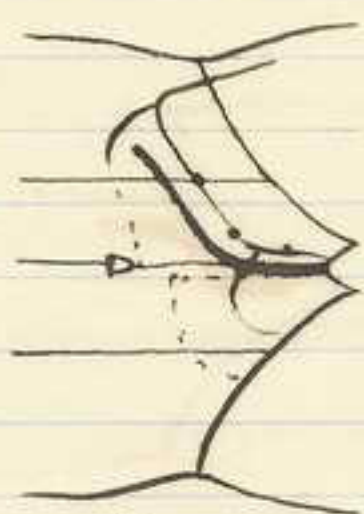

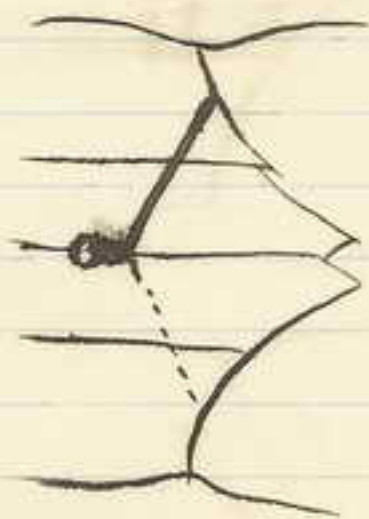
Handwritten text in the center of the page, possibly a list or index, including the number '10' at the bottom.





Kehr. Atlas Pk ch. 1912 pg 74
von Journal 1912






Kehr (A. für K. Ch.) 1912 / p. 74
Sprengel " " 817
Körtz " " 824

Feb 1919

Colecistectomía mixta de

Gosset



cística

Cuando la colecistectomía de atajo arriba es imposible "por gran tamaño" del colecisto se comienza de arriba abajo, librado el campo se continúa de abajo arriba y se liga en media la ramificación de la parte media.

Nunca seccionar el cístico, sin antes haber reconocido el confluente cisto-hepato-colídoco

USAL
UNIVERSIDAD
DEL SALVADOR



Terminar en un
Hepato colédoco anastomosis //

Baso

E

UNIVERSIDAD
DEL SALVADOR

500000594 P.33B.339